



## REVIEW ARTICLE

# Current Aspects and Therapies for Wound healing

Harvinder Popli and Reena Badhwar\*

**Abstract**

Injury to the skin provides a new challenge, as wound healing is a complex and intricate process. Nonhealing wounds represent a significant cause of morbidity and mortality for a large portion of the population. Delayed wound healing is one of the major therapeutic and economic issues in medicine today. Wound healing requires a concerted effort of remodeling of various components of the connective tissue in the presence of appropriate cytokines and growth factors. Unfortunately we still do not understand the actual mechanism of wound healing. This review is an effort to provide information about current challenges of wound healing and their management, recent advances in wound care technology and current management guidelines for the treatment of wounds and ulcers. Various steps like microbial control, subsidence of inflammation, regeneration of connective tissue, angiogenesis and epithelialisation should take place in a time-bound sequence. The development of new and effective interventions in Wound care remains an area of intense research

**Keywords:** Non healing wounds and ulcer; current challenges; mechanism; cytokines; growth factors

## Introduction

Wound healing is a highly dynamic process and involves complex interactions of extracellular matrix molecules, soluble mediators, various resident cells, and infiltrating leukocyte subtypes [1]. Wound-healing process consists of four highly integrated and overlapping phases: homeostasis, inflammation, cell proliferation, and lesion contraction or tissue remodeling [2]. There are many factors that can affect wound healing. Wound healing a matter of concern even with advance therapies [3]. There are many factors that can affect wound healing which interfere with one or more phases in this process, thus causing improper or impaired tissue repair [4]. Currently, there are various challenges in wound healing such as antibiotics resistance, different wound healing rate and wound healing abilities of patients.

## Epidemiology of wound healing

According to the Wound Healing Society, about 15% of older adults in the US suffer from chronic wounds, including predominantly venous stasis ulcers, pressure ulcers (bedsores), and diabetic (neuropathic) foot ulcers. Every year 2 to 3 million more Americans are diagnosed with various types of chronic wounds [5, 6]. Most of the ulcers in India are undoubtedly due to venous etiology, but many other causes such as filariasis, tuberculosis, and leprosy, not frequently seen in the western countries, add to the misery of the Indian patient. The study from India shows that etiology of chronic wounds included systemic conditions such as diabetes and atherosclerosis. Other major causes included pressure ulcers, vasculitis, and trauma [7]. There are few Indian studies on the epidemiology of chronic wounds, one study estimated the prevalence at 4.5/1000 population while, the incidence of acute wounds was more than double at 10.5/1000 population [8, 9].

\*Correspondence: reenabadhwar000@gmail.com

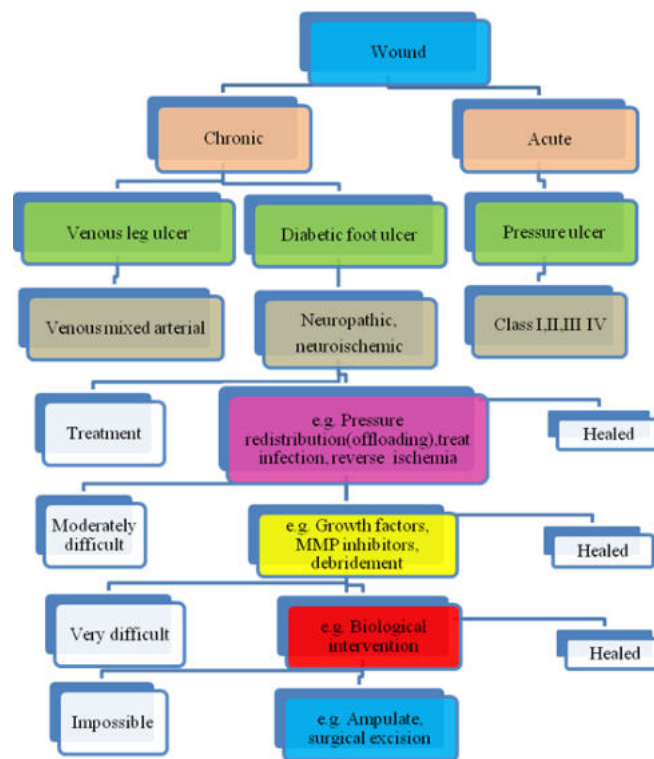
Delhi Pharmaceutical Sciences, Department of Pharmaceutics,  
Research University, New Delhi, India

Full list of author information is available at the end of the article.

Received: 30 Dec 2017, Accepted: 10 May 2018



## Categories of wounds



**Figure 1** Flow diagram of chronic wound management. Chronic wound are classified into three categories (green box): venous leg ulcers (VLUs), diabetic foot ulcers (DFUs) and pressure ulcers (PSUs). Further in (grey boxes) chronic wounds are classified into subcategories based on their suspected etiology. At earlier stages all wounds are assumed to be 'easy' to treat and receive the appropriate care such as 'offloading', antibiotics and surgery. Consequently, if healing failed, wounds get gradually more aggressive treatment, such as debridement and biological intervention. If all treatments fail, then amputation takes place.

## Different Phases of Wound Healing

### Inflammatory phase

Inflammatory phase is the initial phase after cutaneous injury is dominated by inflammatory reactions mediated by growth factors, cytokines, chemokines and their actions on cellular receptors. At this phase Intracellular signaling cascades are activated, contributing to cell proliferation, migration, and differentiation. During the inflammatory phase of wound healing, a variety of membrane-bound receptors play a role in recruiting leukocytes and other cells [10, 11]. The product used in inflammatory phase is Promogran, containing growth factors such as (G-CSF, TGF- $\beta$ 1 and  $\beta$ 2).

### Proliferative phase

The Proliferative phase has three stages such as neoangiogenesis, formation of granulation tissue and re-epithelialization. At neoangiogenesis stage macrophages rediscovered in their interaction with fibroblasts [12]. In the proliferative phase nutrients and oxygen are limiting factors because of the tremendous metabolic activity. A number of other relevant factors important

for fibroblast proliferation in cutaneous wound healing such as extracellular matrix (ECM) and secreted protein acidic and rich in cysteine (SPARC) [13]. The products which are useful at the 2<sup>nd</sup> stage of wound healing are Dermagraft, TransCyte, Allo-derm, Apligraf, OrCel containing platelets derived growth factor (PDGF), fibroblast growth factor, (FGF) and vascular endothelial growth factor VEGF.

### Re-epithelization phase

In this stage covering the wound surface occurs with a layer of epithelium which is based on the differentiation, proliferation, and migration of epidermal keratinocytes [14]. After the wound bed has been properly established with proliferating fibroblasts, a new collagen matrix and the process of re-epithelialization start [15]. The products which are helpful to treat the wound at this stage are Epicel, Laserskin, CellSpray, BioSeed-S, Lypho-Derm, and Trancell combination of different growth factor such as epidermal growth factor (EGF), keratinocytes growth factor (KGF) and granulocyte macrophage colony stimulating factor (GM-CSF).

### Remodeling and scarring phase

This phase starts as early as a few days after injury and lasts up to 2-2.5 years. In this phase, a variety of proteinases such as matrix metalloproteinase (MMP), tissue inhibitor of matrix metalloproteinase (TIMP) contribute to wound healing [16, 17]. The (MMPs) play a central role in wound healing since they degrade certain constituents of interim wound tissue, such as collagen I, III, IV, and VII [18]. MMP2 (gelatinase 2) has been proved an important factor for targeting of angiogenesis, inflammation, and fibrosis in wound healing [19]. The currently useful products in the treatment of wound at this stage is Silicone based products, such as silicone gel sheet (Cica-care) based on transforming growth factor (TGF-3).

## Challenges in the Treatment of Wound Healing

Wound healing involves growth factors, oxygen accessibility, substrates and a suitable healing environment. During wound healing process most of these factors are assumed to be present and contributes a great role in wound healing. There are some major challenges related to treatment of wound such as recurrence of wound after treatment (fore foot malperforans ulcer), [20] patients' wound healing abilities and potential, variation in wound treatment, rate of wound healing, infection influence on healing process, weak angiogenesis system, role of Immune system and antibiotics resistance etc. [21]. But now there is one concern is towards appropriate environment through therapeutic agents and debridement to heal the wound [22].

### Role of angiogenesis system

New blood vessel formation is a critical component of wound healing. During wound healing, angiogenic capillary sprouts invade the fibrin/fibronectin-rich wound clot and within few days organize into a micro vascular network throughout the granulation tissue. As collagen accumulates in the granulation tissue to produce scar, the density of blood vessels diminishes [23]. A dynamic interaction occurs among endothelial cells and angiogenic stimulating factors leading to morphogenetic changes in blood vessels during wound repair. There are various angiogenesis stimulating factors such as fibroblast growth factors i.e. acidic fibroblast growth factors and basic fibroblast growth factors, vascular endothelial growth factors (VEGFs), human mast cell tryptase [24], angiogenin and angiotensin II (ANG II), and platelets derived growth factors (PDGF) etc. Besides the growth factors and chemo tactic factors an appropriate extracellular matrix (ECM) is also equally helpful in angiogenesis [25].

### Antibiotics resistance

Antimicrobial resistance is now a global threat. Bacterial resistance to antibiotics is becoming a major challenge in all parts of the world with the impact on the practice of medicine being seen most acutely [26]. The achievements of modern medicine are put at risk by antimicrobial resistance. The overuse and misuse of antimicrobial drugs accelerates the emergence of drug-resistant strains. Antibiotic-resistant bacteria (*Streptococcus pneumoniae*, *S. aureus*, Gram-negative bacteria such as *Pseudomonas aeruginosa* and *Acinetobacter baumannii*, bacteria in diabetic foot infection) represent an increasing concern in wound infections. Wound colonization with these organisms normally results in aggressive management of the wound complicated by a greatly limited choice of therapeutic antibiotics [27]. Wound infection with antibiotic-resistant bacteria may cause further morbidity in the patient and result in additional treatment costs as a result of measures being instituted to reduce patient-to-patient transmission and control nosocomial outbreaks in the ward or institution [28].

### Role of immune system

Immune cells have an integral function in wound healing beyond their role in inflammation and host defense. Immune cells are vital to the regulation of the wound-healing process through the secretion of signaling molecules, such as cytokines, lymphokines, and growth factors [29]. The immune system is divided into two defense arms i.e. humoral and cellular. Humoral arms comprises competence and antibodies leading to wound healing while cellular arm comprises three defense arm such as neutrophils, macrophages and lymphocytes [30]. Neutrophils are the first immune cells that reach the wound site and helps to reduce the infection whereas macrophages plays critical and important role in wound healing. The antimicrobial function of macrophages is carried out by phagocytosis and generation of reactive radicals such as peroxides, oxygen and nitric oxides [31]. The main role of macrophages in wound healing is secretion of growth factors and cytokines that leads to proliferation and collagen synthesis [32].

### Influence of infection

Wound infection is a complex process that results from a detrimental interaction between the patient and the pathogen(s) that can delay healing and cause wound pain [33]. Wound infection is one of the most challenging aspects of wound management and a major contributor to healthcare costs globally [34]. The main underlying cause of infection related wound pain is the inflammatory response stimulated by the infecting microorganisms. This response causes the release of inflammatory mediators and stimulates the production of enzymes and free radicals, which

can cause tissue damage. Further indicators of wound infection that may impact on comfort and, by causing distress, contribute to pain include: friable granulation tissue that bleeds easily; increased exudate production; abnormal smell; and wound breakdown [35]. In particular, wound exudate produced in response to colonization or local infection of a wound may contribute to wound pain. Chronic wound exudate contains increased levels of free radicals and numerous enzymes, such as matrix metalloproteinase (MMPs), that can damage healthy wound tissue and may be harmful to the surrounding skin [36]. It is important to determine at which point critical colonization has been reached or the level at which the type and quantity of bacteria begin to cause active infection.. Surrounding erythema, swelling, induration, tenderness, and malodor are the expected characteristics of an infected wound [37].

## Management of Wound Healing

Management of wound is a multidisciplinary approach. It involves the following aspects. The initial step in the management of any wound is to remove the local impediments to wound healing by eliminating devascularized tissue, necrotic material, and excessive bacterial burden [38, 39]. Modern wound dressing preparation strategies involve a thorough and yet judicious debridement, preserving vital tissue while ridding the wound site of the accumulated impediments to optimal healing. At present, numerous modalities are available for debriding wounds such as Tissue engineering substitutes, various types of antiseptics products, various non surgical approaches and different types of wound dressings [40].

### Mechanical and current therapy in the treatment of wounds

Topical treatments and dressings are essential for the management of wound exudate, and can be used to promote a moist environment. In addition to moisture, adequate tissue blood flow and oxygen levels are required for healing, and to avoid infection and further tissue damage. All these therapies are associated with significant expense and are being utilized in some situations without sufficient scientific evidence demonstrating their efficacy. Therefore, the search for an efficacious, convenient and cost-effective therapy continues.

#### *Radiant heat dressing*

The use of heat in wound healing has been demonstrated to aid oxygen flow and hence healing in acute wounds. Control of ambient temperature or application of heat locally may benefit healing and, in particular, increase patients' resistance to infection [41]. In acute wound condition reductions in body temper-

ature during and following surgery elicit thermoregulatory responses that include cutaneous vasoconstriction, evidenced by low tissue-oxygen levels and a delay in the return to normal levels [42, 43].

#### *Hyperbaric oxygen therapy (HBOT)*

This therapy is occasionally used as an adjunct to standard wound care. HBOT, which involves breathing 100% oxygen at supra-atmospheric pressures while inside of a compression chamber, is based on the rationale that tissue hypoxia contributes to the failure of many chronic wounds to heal [44]. HBOT appears to decrease the rate of major amputation related to diabetic foot ulcers and may improve the chance of diabetic foot ulcer healing at 1 year [45]. HBOT is associated with several potential adverse effects, including oxygen toxicity to brain and lung as well as barotraumas to the ears, lungs, and sinuses. In addition, temporary myopia is a very common adverse effect [44].

#### *Negative pressure wound therapy (NPWT)*

Negative Pressure Wound Therapy (NPWT) is a newer noninvasive adjunctive therapy system that uses controlled negative pressure using Vacuum-Assisted Closure device (VAC) to help promote wound healing by removing fluid from open wounds through a sealed dressing and tubing which is connected to a collection container. The role of negative pressure dressing in healing of diabetic foot ulcers has been proposed as a novel method of manipulating the chronic wound environment in a way that it reduces bacterial burden and chronic interstitial wound fluid, increases vascularity and cytokine expression and to an extent mechanically exploiting the viscoelasticity of peri wound tissues [46]. Application of negative pressure over wound bed allows the arterioles to dilate, so increasing the effectiveness of local circulation, promoting angiogenesis, which assists in the proliferation of granulation tissue [47, 48].

#### *Topical oxygen therapy*

Oxygen supply for chronic non-healing wounds has recently been a focus of interest for many investigators. The partial pressure of oxygen (pO<sub>2</sub>) is a key factor in wound healing and the literature has consistently reported that a transcutaneous (pO<sub>2</sub>) below 40 mm Hg is strongly associated with poor wound healing [49]. While increasing pO<sub>2</sub> at the wound edge improves hypoxia, it also promotes several other aspects of wound healing through the production of reactive oxygen species (ROS). Recent evidence, indeed, revealed that oxygen is not merely the primary source of energy, but also generates several ROS which may function as intracellular messengers in normal cell signal transduction and cell cycling. During wound healing the presence of oxygen takes on additional importance because of the

increased demand of reparative processes like cell proliferation and synthesis of collagen [50, 51].

*Gauze*

Gauze is a thin, translucent fabric with a loose open weave. It is historically been one of the most popular wound dressing [52] Being inexpensive, it is still the most commonly used dressing in hospitals. These dressings are available in both pad and ribbon form. Gauze ribbons are ideal for treating deep wounds and sinus tracts, which heal from the base upwards in order to eliminate dead space and prevent abscess formation [53]. Loose packing with gauze ribbons encourages healing from the base outward. Packing should never be tight, because this may cause localized ischemia and wound enlargement. Some marketed gauzes are given in (Table 1). [54]

**Table 1** Different type of marketed gauzes

Mesalt	Hypertonic sodium chloride-impregnated gauze. Highly absorbent	Mo Inlycke
Xeroform Vaseline gauzes	Less adherent than plain gauze Gauze impregnated with petrolatum, less adherent than plain gauze	Kendall Kendall

*Films*

Films are transparent, conformable, adhesive dressings that may be used as primary dressings directly over a wound. Film dressings are non absorbent; they manage moisture by vapor transmission only [54]. So, films should be reserved for wounds with minimal exudate. Films are used inappropriately over a wound with heavy exudate; they may cause fluid trapping and maceration [55] There is been a tendency to strip delicate new epidermis from newly re-epithelialized areas of a healing wound if films are applied and removed too frequently [56]me markets films and their products are given below in (Table 2).

**Table 2** Films and their products

Blister film	Adhesive-free wound contact area	Kendall
OpSite Flexi grid Biocclusive	Printed with wound measurement grid to track healing Classic film dressing	Smith & Nephew J & J

*Hydrogels*

Hydrogels are debriding agents used in the management of wounds. They are water-based products used to maintain a moist wound-healing environment. They are best suited for dry wounds or wounds with low levels of exudate, and should be

avoided in wounds with heavy exudate because the excess moisture can lead to maceration of periwound skin [57, 58] Hydrogels are available in two forms, amorphous and sheet hydrogel. Amorphous hydrogel are soft formless gel that become less viscous as they absorb fluid, while sheet hydrogels are firm sheets of gel that swell when fluid is absorbed. Hydrogel also promote autolytic debridement of slough and necrotic tissue, making them suitable debriding agents in patients for whom sharp debridement is contraindicated [58] key advantage of hydrogels is that they can be applied and removed with minimal pain or trauma to the wound bed. Several small studies have shown Hydrogels to perform similarly to moist gauze and hydrocolloid dressings in rate of pressure ulcer healing [59, 60]. Some of the marketed hydrogels and their products are given in (Table 3).

**Table 3** Hydrogels and their products

X cell cellulose dressing	Moisture-retentive No traumatic removal Pain relief	Xylos
Carrasyn	Amorphous gel, contains aloe Vera gel extract	Car-rington

*Hydrocolloids*

Hydrocolloids in contrast to the fluid-donating Hydrogel, provides absorption. They are used over wounds with low to moderate amounts of exudate. These adhesive, occlusive, conformable dressings absorb wound exudate to forma hydrophilic gel that helps to maintain a moist healing environment [61, 62]. A major advantage of hydrocolloid dressings that it can protect against shear force at the skin surface, which is a contributor to pressure ulcer development [63] me hydro colloidal marketed preparations are in (Table 4).

**Table 4** Hydrocolloids and their products [64]

Tegasorb	Transparency after use.	3M
Comfeel Plus	Contains alginate for increased absorption	Coloplast

*Alginates*

Alginates made from brown seaweed are highly absorbent, fibrous dressings that can hold up to 20 times their weight in fluid [65]. Alginate dressings are utilized mainly for their strong absorptive capacity on wounds with moderate to heavy levels of exudat [66, 67]. It is important that these very absorptive dressings be kept from desiccating over the wound; because the resultant dry environment could delay wound haling [57]. A unique advantage of alginate dressings is that they are inherently haeo-static [68, 69] and can be used to control minor bleeding.

**Table 5** Alginates and their products

Aquacel Hydro fiber	More absorptive than alginates	ConvaTec
Kaltostat Sorbsan	High guluronic acid content High mannuronic acid content	ConvaTec Bertek
AlgiSite	High mannuronic acid content	Smith & Nephew

### Foams

Foams are moderately absorbent, semi occlusive dressings that may be used over light to moderately draining wounds. They are made from semi permeable polyurethane and used for their cushioning effect as the dressings allow water vapor to enter but keep out bacteria and other contaminants though they are not intended as a substitute for proper pressure-relieving devices [70]. The fluid absorption capacity of these dressing varies with foam thickness [71]. Some foam has a film backing to prevent exudates leakage and to provide an additional barrier to bacterial contamination.

## Currently available antiseptics products for treating wound

Quality care is a critical requirement for wound healing and 'good' care of wounds has been synonymous with topical prevention and management of microbial contamination. Topical antiseptics are antimicrobial agents that kill, inhibit or reduce the number of microorganisms and are thought to be essential for wounds infection control. However, they have long and commonly been used on wounds to prevent or treat infection. Repeated and excessive treatment of wounds with antiseptics without proper indications may promote a microenvironment similar to those found in chronic wounds. However, when applied at the proper times and concentrations, some classes of antiseptics may provide a tool for the clinician to drive the wound bed in desired directions. There are list of antiseptics which are useful in treatment of wound in (Table 7) [71–74]

## Biological Products for different phases of wound healing

Chronic wounds may be arrested in any of the four phases; commonly, however, disruption occurs in the inflammatory or the proliferative phases. Many mediators—including inflammatory cells, growth factors, proteases such as matrix metalloproteinase (MMPs), and cellular and extracellular elements—play important roles in different stages of the healing process. Alterations in one or more of these components may account for the im-

paired healing observed in chronic wounds. More recently, artificial growth factors such as G-CSF, TGF- $\beta$ 1 and  $\beta$ 2, PDGF, FGF, and VEGF etc. have been developed to help achieve healing in chronic, non-healing wounds of varying aetiologies [75] in (Table 8).

## Tissue engineering substitutes in wound healing

Since long time human amniotic membrane and frog skin have long been used to treat burn wounds. Recently growth factors and artificial "skin substitutes" have been developed to achieve healing in chronic and non-healing wounds. These following artificial skin substitutes consist of a micro engineered, biocompatible, polymer matrix in combination with cellular or extracellular elements such as collagen. Followings are the tissue engineered skin substitutes in wound healing in (Table 9) [76]

## Conclusion

In this review, we have discussed various current aspects and therapies for wound healing. Wound healing is a complex biological process that consists of homeostasis, inflammation, proliferation, and remodeling. Large numbers of cell types—including neutrophils, macrophages, lymphocytes, keratinocytes, fibroblasts, and endothelial cells—are involved in this process. Recent studies identified the crucial role of several growth factors, various types of physico – mechanic therapies besides antimicrobial / antibiotics. Complex wounds represent a major challenge for the clinician and wound care specialist. Despite, all the recent advances in wound care therapies and our understanding of the pathophysiology of chronic wounds; nothing can supplant the need for adhering to the basic tenets of wound care. Medical and nutritional optimization, debridement (including surgery), management of ischemia, management of infection, offloading (or compression), and appropriate wound bed preparation are the current practices followed but there is no uniform protocol. We discussed many current therapies for wound healing but recurrence of wound raise a question on these current therapies. Regulating the activity of cells involved in wound healing seems to be a hot topic in future wound therapy as many new and interesting factors are being discovered. Hence, chronic wounds represent such a profound, unsolved, and rapidly increasing health problem with exuberant morbidity, mortality and cost. There is a need to explore the application of current therapies to enhance the success rate of wound healing. We believe that this area of research may continue to be fruitful for many researchers to develop various treatments for wound healing.

**Table 6** Foam dressings [72]

Allevyn hydro cellular dressing	Trilaminar structure with nonadherent wound contact layer, absorbent central layer, and semi permeable film outer layer	Smith &Nephew
Allevyn cavity dressing	Absorbent foam chips covered with nonadherent wound contact layer)	Smith &Nephew
Lyfoam C	Contains activated carbon for odor control	ConvaTec

**Table 7** Sliver dressings

Products	Company	Formulation	Advantages	Disadvantages
Aquacel Ag Hydro fiber	ConvaTec	Silver impregnated hydro fiber dressing	Slow release of silver ions	Levels of silver ions at wound interface not well defined [71]
Contreet Foam	Coloplast	Rapid release of silver ions.	Less painful	May delay epithelialization [72]
Silverlon wound Contact dressing	Argentum	Silver-coated wound contact layer, absorbent pad, and film backing Silver-containing hydrogel	Few adverse effects than silver nitrate	Relatively expensive
Silvasorb	Medline	Relatively low silver content	Microbial resistance is rare	May cause silver staining of Tissues
Silvercel	Johnson & Johnson	Coated with nanocrystalline silver	Microbial resistance is rare	May cause silver staining of Tissues [73]
Acticoat 7	Smith & Nephew	Rapid release of silver ions	Less painful	Rapid release of silver ions[74]

**Table 8** G-CSF - granulocyte colony stimulating factor, TGF-  $\beta$ 1 and  $\beta$ 2 transforming growth factor, PDGF - platelet derived growth factor; FGF - fibroblast growth factor; VEGF - vascular endothelial growth factor; EGF - epidermal growth factor; KGF- keratinocytes growth factor; GM-CSF - granulocyte macrophage colony stimulating factor; TGF- transforming growth factor [76].

Sr.No	Phase	Products	Growth factors
1	Inflammatory phase	Promogran	G-CSF, TGF- $\beta$ 1 and $\beta$ 2
2	Proliferative phase	Dermagraft, TransCyte, Alloderm, Apligraf, OrCel	PDGF, FGF, VEGF
3	Epithelialisation	Epicel, Laserskin, CellSpray, BioSeed-S, LyphoDerm, Trancell	EGF, KGF, GM-CSF
4	Remodeling and scarring	Silicone based products, such as silicone gel sheet (Cica-care)	TGF-3

**Table 9** Tissue engineered skin substitutes in wound healing. \*Epidermal; †Dermal, a cellular; ‡Dermal, cellular; §Composite [75, 76].

Products	Advantages	Disadvantages
Integra†	Immediate permanent coverage for reconstructive surgery	Autograft is needed after 3-4 weeks for epithelial cover
TransCyte‡	To coat surgically excised full thickness burns and non-excised limited thickness burns	Not appropriate for infected wounds and patients who are allergic to porcine collagen
Epicel, Laserskin*	Permanent coverage for superficial and partial thickness burns	2-3 week lag phase between biopsy and obtaining epidermis
AlloDerm†	permanently cover full thickness burns and deep ulcers	Autograft is required for epithelial cover and not appropriate for infected wounds
Apligraf§	Chronic wounds such as diabetic foot ulcer and venous leg ulcer	Not for patients allergic to bovine collagen
OrCel§	Acute and chronic deep dermal ulcers, partial thickness burns	Not for infected wounds or patients allergic to bovine collagen
Biobrane†	To coat widespread partial thickness burns and donor sites	suitable for infected burn wounds

## Acknowledgments

One of the author miss Reena Badhwar kindly acknowledges to Delhi Pharmaceutical Sciences & Research University, New Delhi-17, India for providing financial assistance in the form of senior research fellowship for her doctoral study. No writing assistance was utilized in the production of this manuscript.

## References

- [1] Eming SA, Krieg T, M J. Davidson: Inflammation in Wound Repair Molecular and Cellular Mechanisms.. vol. 127; 2007.
- [2] A DF. Modolo LV, Sanches ACC, Porto RR: Wound healing agents, the role of natural and non-natural products in drug development. Mini Rev Med Chem. 2008;8:879–88.

- [3] Strauss MB, Miller MS, Aksenov MV. Challenges of wound healing. *Challenges of*; 2011.
- [4] Menke NB, Ward KR, Witten TM, Bonchev DG, Diegelmann RF: Impaired wound healing. *Clin. Dermatol*; 2007.
- [5] Cheng CF, D. Sahu: To accelerate effectively both acute and diabetic wound healing in mice;”. *The Journal of Clinical Investigation*. 2011;121(11):4348–4361.
- [6] Agale SV. *Chronic Leg Ulcers: Epidemiology, Aetiopathogenesis, and Management*. Hindawi Publishing Corporation Ulcers; 2013.
- [7] Langer V. Leg ulcers, An Indian perspective. *Indian Dermatol Online J*. 2014;5(4):535.
- [8] Shukla VK, Ansari MA, Gupta SK. Wound healing research: A perspective from India. *Int. J Low Extreme Wounds*. 2005;4:7–8.
- [9] Strauss MB. *Challenges of wound healing*; 2010. .
- [10] Nedelec B, Oliveira AD, Saint-Cyr M. Garrel D: Differential effect of burn injury on fibroblasts from wounds and normal skin; *Plast. Reconstr Surg*. 2007;119:2101–9.
- [11] Yukami T, Hasegawa M, Matsushita Y, Fujita T, Matsushita T, Horikawa M. et al.: Endothelial selectins regulate skin wound healing in cooperation with L-selectin and ICAM-1. *J Leukoc Biol*. 2007;82:519–31.
- [12] Mosser DM, Edwards. JP: Exploring the full spectrum of macrophage activation. *Nat. Rev Immunol*. 2008;8:958–69.
- [13] Bradshaw AD, Reed MJ, Sage. EA: SPARC-null mice exhibit accelerated cutaneous wound closure. *J Histochem Cytochem*. 2002;50:1–10.
- [14] Fathke C, Wilson L, Shah K, Kim B, Hocking A, Moon R. Wnt: signaling induces epithelial differentiation during cutaneous wound healing. *BMC Cell Biol*. 2006;7:1017–26.
- [15] Inada R, Matsuki M, Yamada K, Morishima Y, Shen SC, Kuramoto N. et al: Facilitated wound healing by activation of the transglutaminase gene. *Am J Pathol*. 2000;157:1875–82.
- [16] Dissemond J, Witthoff M, Brauns T, Haberer D. pH Value of chronic wound milieu. *Hautarzt*; 2003.
- [17] Vuotila T, Ylikontiola L, Sorsa T, Luoto H, Hanemaaijer R, Salo T. The relationship between MMPs and pH in whole saliva of radiated head and neck cancer patients. *J Oral Pathol Med*. 2002;31:329–38.
- [18] Baker EA, Leaper DJ. Proteinases, their inhibitors, and cytokine profiles in acute wound fluid. *Wound Repair Regen*. 2000;8:392–8.
- [19] Jansen P, Rosch R, Jansen M, M B, Junge K, Alfonso-Jaume A. Regulation of MMP-2 gene transcription in dermal wounds. *J Invest Dermatol*. 2007;127:1762–7.
- [20] Kuwahara M, Tada H, Mashiba K. Mortality and recurrence rate after pressure ulcer operation for elderly long-term bedridden patients. *Ann Plast Surg*;2005(54):629–32.
- [21] Nunan1 R, Martin KGHP. Clinical challenges of chronic wounds, searching for an optimal animal model to recapitulate their complexity. *Disease Models & Mechanisms*;2014(7):1205–1213.
- [22] Robson MC. Wound infection: a failure of wound healing caused by an imbalance of bacteria. *Surg Clin North Am*. 1997;77:637–50.
- [23] Brooks PC, Clark RAF, Cheresch DA: Requirement of vascular integrin avb for angiogenesis *Science*; 1994.
- [24] Blair RJ, Meng H, Marchese MJ, Ren S, Schwartz LB, Tonnesen MG, et al. BL: Human mast cells stimulate vascular tube formation Tryptase is a novel, potent angiogenic factor. *J Clin Invest*;1997(99):2691–2700.
- [25] Tonnesen MG, Feng X, Clark RAF. Angiogenesis in Wound Healing. *J of Investigative Dermatology*. 2000;5:40–46.
- [26] Wright JB, Lam K, Burrell BRE. PhD: Wound management in the era of increasing bacterial antibiotics resistance, a role for topical silver treatment; 1998.
- [27] Leaper DJ. Prophylactic and therapeutic role of antibiotics in wound care. *Am J Surg*. 1994;p. 1–15.
- [28] Howell-Jones RS, Wilson MJ, Hill KE, Howard AJ, Price PE, Thomas DW. A review of the microbiology, antibiotic usage and resistance in chronic skin wounds. *Journal of Antimicrobial Chemotherapy*. 2005;55:143–149.
- [29] Farrerasa N, Vicenc-Artigasb, Cardonac D, Riusb X, Triasb M, A J. Gonza, leza: Effect of early postoperative enteral immunonutrition on wound healing in patients undergoing surgery for gastric cancer. *Clinical Nutrition*. 2005;24:55–65.
- [30] N ASMJ. Mansbridge: The Innate Immune System in Acute and Chronic Wounds. *Advances in wound care*; 2014.
- [31] Park JE, D AM. Barbul, M.D: Understanding the role of immune regulation in wound healing. *The American Journal of Surgery*. 2004;187:11–16.
- [32] Barbul A. Immune aspects of wound repair: *Clin Plast Surg*; 1990.
- [33] Cooper R. Understanding wound infection. In *European Wound Management Association (EWMA). Position Document: Identifying criteria for wound infection*; 2005.
- [34] Zafran SZEN, Garmi G. Raed Salim: Postcesarean wound infection, prevalence, impact, prevention, and management challenges. *International Journal of Women’s Health*;2017(9):81–88.



- [35] Cutting K, White RJ, Mahoney P, Harding KG: Clinical identification of wound infection, a Delphi approach. In: European Wound Management Association (EWMA) Position. 2005;p. 6–9.
- [36] White RJ: Wound infection-associated pain. *J Wound Care*. 2009;18(6):245–49.
- [37] Cutting KF, Harding KG: Criteria for identifying wound infection. *J Wound Care*. 1994;3(4):198–201.
- [38] Ayello EA, Dowsett C, Schultz GS: Time heals all wounds. *Nursing*. vol. 34; 2004.
- [39] Viswanathan PV. FRCP (London), FRCP (Glasgow): Epidemiology of Diabetic Foot and Management of Foot Problems in India. *The International Journal of Lower Extremity Wounds*;9(3):122–126.
- [40] Steed DL. Debridement. *Am J Surg*. 2004;187:71–4.
- [41] Bergstrom N, Bennett MA, Carlson CE. Treatment of Pressure Ulcers: Clinical practice guidance; 1994.
- [42] West JM. Wound healing in the surgical patient: influence of the perioperative stress response on perfusion; 1990.
- [43] Professor of Wound Healing and Director Wound Healing Research. *Journal of*. 2000;9.
- [44] Kranke P, Bennett M, Roeckl Wiedmann I, Debus S: Hyperbaric oxygen therapy for chronic wounds. *Cochrane Database Syst Rev*; 2004.
- [45] Cronje FJ. Oxygen therapy and wound healing—topical oxygen is not hyperbaric oxygen therapy. *S Afr Med J*;2005(95):840.
- [46] Armstrong DG, Lavery LA: Negative pressure wound therapy after partial diabetic foot amputation. A multicenter randomized controlled trial. *Lancet*; 2005.
- [47] Morykwas MJ, Argenta LC, Shelton-Brown EI, McGuirt W: Vacuum-assisted closure, A new method for wound control and treatment, Animal studies and basic foundation. vol. 38. *Ann Plast Surg*; 1997.
- [48] Shirin Garg: Role of Negative Pressure Wound Therapy in Healing of Diabetic Foot Ulcers. *J Surg Tech Case Rep*2011;3(1):17–2.
- [49] Piantadosi CA: Topical oxygen is not hyperbaric oxygen (HBO2). *Undersea Hyperb Med*; 2003.
- [50] Hunt TK, Zederfeldt B, Goldstick TK: Oxygen and healing. *Am J Surg*. 1969;118:521–525.
- [51] Samil Aktas, MDd: Topical Oxygen for Chronic Wounds: A PRO/CON Debate. *Journal of the American College of Clinical Wound Specialists*;2015(5):61–5.
- [52] Winter GD. Epidermal regeneration studied in the domestic pig. Chicago: Year Book Medical Publishers; 1972. p. 71–112.
- [53] Bolton L, McNees P, Rijswijk L, Leon J, Lyder C, Kobza L: Wound-healing outcomes using standardized assessment and care in clinical practice. *J Wound Ostomy Continence Nurs*;2004(31):65–71.
- [54] Rovee DT. Evolution of wound dressings and their effects on the healing process. *Clin Mater*; 1991.
- [55] Kannon GA, Garrett AB: Moist wound healing with occlusive dressings: a clinical review. *Dermatol Surg*; 1995.
- [56] Alvarez OM, Mertz PM, Eaglstein WH: The effect of occlusive dressings on collagen synthesis and re-epithelialization in superficial wounds. *J Surg Res*1983;35:142–8.
- [57] Baker PD. Creating the optimal environment: an overview of dressings for chronic wounds. *Adv Nurse Pract*; 2005.
- [58] Jones V, Milton T. When and how to use hydrogels. *Nurs Times*. 2000;96:3–4.
- [59] Motta G, Dunham L, Dye T, Mentz J, O’Connell-Gifford E, Smith E: Clinical efficacy and cost-effectiveness of a new synthetic polymer sheet wound dressing. *Ostomy Wound Manage*1999;45:41–9.
- [60] Kaya AZ, Turani N, Akyuz M: The effectiveness of a hydrogel dressing compared with standard management of pressure ulcers. *J Wound Care*. 2005;14:42–4.
- [61] Szycher M, Lee SJ: Modern wound dressings, a systematic approach to wound healing. *J Biomater Appl*. 1992;7:142–213.
- [62] Hess CT. Wound care. Baltimore, MD: Lippincott Williams and Wilkins; 2005.
- [63] Ohura N, Ichioka S, Nakatsuka T, Shibata M: Evaluating dressing materials for the prevention of shear force in the treatment of pressure ulcers. *J Wound Care*. 2005;14:401–4.
- [64] Banks V, Hagelstein S, Thomas N, Bale S, KG H. Comparing hydrocolloid dressings in management of exuding wounds. *Br J Nurs*. 1999;1999(8):640–6.
- [65] Pirone LA, Bolton LL, Monte KA, Shannon RJ: Effect of calcium alginate dressings on partial-thickness wounds in swine. *J Invest Surg*. 1992;5:149–53.
- [66] Taylor BA. Selecting wound healing products: choices for long-term care settings. *Adv Nurse Pract*; 2003.
- [67] Segal HC, Hunt BJ, Gilding K: The effects of alginate and nonalginate wound dressings on blood coagulation and platelet activation. *J Biomater Appl*1998;12:249–57.
- [68] Fletcher J. Understanding wound dressings: foam dressings. *Nurs Times*. 2005;101:50–1.
- [69] Eaglstein WH, Mertz PM, Falanga V. Occlusive dressings. Am. vol. 35. *Fam Physician*; 1987.
- [70] Twinsburg. Ohio Edgepark Surgical Catalog ; 2005.
- [71] Thomas S, McCubbin P. A: A comparison of the antimicrobial effects of four silver-containing dressings on three organisms. *J Wound Care*. 2003;12:101–7.

- [72] Lansdown AB, Jensen K, Jensen. MQ: Contreet Foam and Contreet Hydrocolloid: an insight into two new silver containing dressings. *J Wound Care*. 2003;12:205–10.
- [73] Thomas S, McCubbin. P: An in vitro analysis of the antimicrobial properties of 10 silver-containing dressings. *J Wound Care*2003;12:305–8.
- [74] Ip M, Lui SL, Poon VK, Lung I, Burd. A: Antimicrobial activities of silver dressings: an in vitro comparison. *J Med Micro*. 2006;.
- [75] Enoch S, Shaaban H, Dunn. KW: Informed consent should be obtained from patients to use products (skin substitutes) and dressings containing biological material. *J Med Ethics*. 2005;31(1):2–6.
- [76] Jones J, Nelson. E: Skin grafting for venous leg ulcers. *Cochrane Database Syst Rev*; 2005.